

Intubating laryngeal mask as a ventilatory device during percutaneous dilatational tracheostomy: a descriptive study

U. Linstedt¹*, F. Möller², N. Grote², M. Zenz² and A. Prengel³

¹Department of Anaesthesiology, Intensive Care Medicine, and Pain Therapy, Diako Hospital, Flensburg, Academic Teaching Hospital of the University of Kiel, Germany. ²Department of Anaesthesiology, Intensive Care Medicine, and Pain Therapy, Knappschaftskrankenhaus Bochum—Langendreer, Ruhr University, Bochum, Germany. ³Department of Anaesthesiology, Intensive Care Medicine, and Pain Therapy, Virngrund Clinic, Ellwangen, Germany

*Corresponding author: Klinik für Anästhesiologie, Operative Intensivmedizin und Schmerztherapie, Diakonissenkrankenhaus, Marienhölungsweg 2, 24393 Flensburg, Germany. E-mail: linstedtul@diako.de

Background. We use an intubating laryngeal mask (ILM) in preference to an endotracheal tube (ETT) as the ventilatory device during percutaneous dilatational tracheostomy (PDT) to overcome potential problems such as difficult ventilation, accidental extubation, damage of the ETT or of the bronchoscope, and need for additional assistant to secure the airway. We report our experience with this method.

Methods. In this prospective observational study, PDT was performed using the ILM in 86 patients. The insertion of the ILM, the quality of ventilation, and the view of the tracheal puncture site were rated as: 'very good', 'good', 'difficult', and 'not possible with ILM'.

Results. The bronchoscope was not damaged during any case, and all PDTs were performed by two physicians, without the need for an additional assistant. PDTs with ILM were successful in 95% of the patients ($n=82$). The ratings were 'very good' or 'good' in 80% of cases with regards to ventilation, in 90% for identification of relevant structures and tracheal puncture site, and in 85% for the view inside the trachea during PDT. Tracheal re-intubation was required for inadequate ventilation with ILM in four patients.

Conclusions. The advantages of this procedure were lack of damage to the bronchoscope, the need for two instead of three persons to perform the PDT, and the excellent view inside the trachea. We recommend the ILM as a standard device for ventilation during bronchoscope-guided PDT.

Br J Anaesth 2007; **99**: 912–15

Keywords: airway, patency; complications, airway obstruction; equipment, laryngeal mask, intubating; equipment, tracheostomy, percutaneous; surgery, tracheotomy

Accepted for publication: June 13, 2007

About 20 000 percutaneous dilatational tracheostomies (PDTs) are performed in Germany per year.¹ All of the methods for PDT include bronchoscope-guided tracheal puncture. This step allows a view inside the trachea, both to ensure a correct, mid-line puncture site and to avoid serious complications such as puncture of the posterior tracheal wall. The bronchoscopy is usually performed through an endotracheal tube (ETT). During this procedure, a number of problems may occur, including: (1) damage to the bronchoscope during tracheal puncture.^{2–4} Our own experience and other reports estimate damage of

one to two bronchoscopes per 100 PDT procedures. (2) Ventilation may be difficult,⁵ because the bronchoscope results in obstruction of the ETT. For example, a bronchoscope with a diameter of 5 mm causes a 50% obstruction inside a 7 mm ETT. (3) Estimating the site for tracheal puncture requires the bronchoscope and the ETT tip to be above the ring cartilage. To minimize the risk of accidental extubation,^{2 6–9} an additional assistant is required to withdraw and secure the ETT. (4) Puncture of the ETT can occur. If this remains unnoticed, it will result in problems during dilatation.^{2 6 7 9 10}

Using a laryngeal mask airway (LMA) instead of an ETT may overcome these problems as the tip of the bronchoscope is above the puncture site so damage to the bronchoscope or airway device by the puncture needle is less likely, the lumen of the LMA is greater than that of the ETT and therefore less obstructed by the bronchoscope (15% approximately), and the tip of the bronchoscope may be placed between the vocal chords without danger of accidental extubation, allowing a view of the puncture site without the need for an additional assistant for securing the airway.

Apart from a few studies,^{9 11–13} the use of the LMA is not widely accepted as an alternative airway for PDT. Instead of the classic LMA, we use the intubating laryngeal mask (ILM), which allows re-intubation of the trachea in an emergency.^{14 15} We report our experience with this method, using descriptive criteria.

Methods

The study was approved by the ethics committee of the Ruhr University Bochum.

After each PDT, both the operating intensivist and the physician performing the bronchoscopy made a standardized rating of the practicability of the ILM. This included the stages of ventilation through the ILM, visibility of and passage through the vocal chords with the bronchoscope, the view of the circumference of the trachea, ring cartilage, first tracheal cartilages, and the overall tracheal view during PDT.

The rating used for the ILM during PDT was:

- (i) very good/easy, without any problem (1 point);
- (ii) good/easy, minor corrections necessary (2 points);
- (iii) difficult, but possible with ILM (3 points);
- (iv) not possible with ILM (4 points).

Rating of ‘ventilation’ was

- (i) decrease of minute ventilation (MV) <20% (1 point);
- (ii) MV decreased, but was >2 litre min⁻¹, Sa_{o₂}>90% (2 points);
- (iii) MV <2 litre min⁻¹, or Sa_{o₂} 80–89% (3 points);
- (iv) Sa_{o₂}<80% (4 points).

If the insertion of, and ventilation with, ILM was not possible, patients were rated 4 points in the item ‘ventilation’ and the following items too.

Mean arterial pressure (MAP), arterial oxygen saturation (Sa_{o₂}), and MV were measured before and 1 min after PDT.

For the procedure, F_{I_{o₂}} was set at 1.0, the ILM was introduced, and the ventilation was checked. Subsequently, a video bronchoscope (BF 18V, Pentax, Japan) was inserted through the ILM into the trachea, and the thyroid cartilage, the cricoid (likewise) cartilage, and the first to third tracheal cartilages were identified. The tip of the bronchoscope was positioned 0–1 cm below the vocal chords.

Table 1 MAP, MV, and arterial oxygen saturation (Sa_{o₂}) [mean (SEM)] before inserting the ILM (F_{I_{o₂}}=1.0) and 5 min after inserting the ILM

	MAP (mm Hg)	MV (litre min ⁻¹)	Sa _{o₂} (%)
Before ILM insertion	84 (16)	8.2 (2.3)	99 (1.5)
5 min after ILM insertion	83 (18)	7.5 (3.1)	98 (5)

The PDT was performed using the method described by Griggs and colleagues¹⁶ (Portex Griggs-Set, Smiths Medical). After skin incision, the tracheal puncture was guided bronchoscopically to the midline between the first and second or second and third tracheal cartilages. A guidewire was introduced through the cannula to dilate the trachea with the forceps and insertion of the tracheal cannula. Before connecting the cannula to the ventilator, the intratracheal position was checked by tracheo-bronchoscopy.

Results

We performed 86 PDTs with an ILM as the ventilatory device in 50 neurosurgical patients, 15 general surgical patients, 15 trauma patients, and six medical patients. The average age of the patients was 62 (sd 16) yr. Indications for PDT were prolonged mechanical ventilation of more than 7 days and two failed extubation attempts, respectively.^{1 17} The total operation time, including the insertion of the ILM, was 25 (sd 12) min, and the time from the puncture of the trachea to the insertion of the tracheal cannula was 11 (sd 9) min. No damage to the bronchoscope occurred. All procedures were performed with two physicians only, without an additional assistant to secure the ILM (Table 1).

Four patients required re-intubation of the trachea due to inability to insert an ILM (n=1) or insufficient ventilation (n=3) (Table 2; Fig. 1). Difficult ventilation, defined as a

Table 2 Rating of stages of PDT. Insufficient ventilation with the ILM requiring re-intubation was rated as 4

	1, very easy/good	2, easy/good	3, difficult	4, impossible easy/good
Ventilation with ILM	40 (47%)	28 (33%)	14 (16%)	4 (5%), reintubation
Visibility of and passage through the vocal chords with bronchoscope	44 (51%)	22 (26%)	16 (19%)	4 (5%)
View of the circumference of the trachea, ring cartilage, and first tracheal cartilage before PDT	65 (76%)	12 (14%)	5 (6%)	4 (5%)
View inside the trachea during PDT	54 (63%)	19 (22%)	9 (10%)	4 (5%)

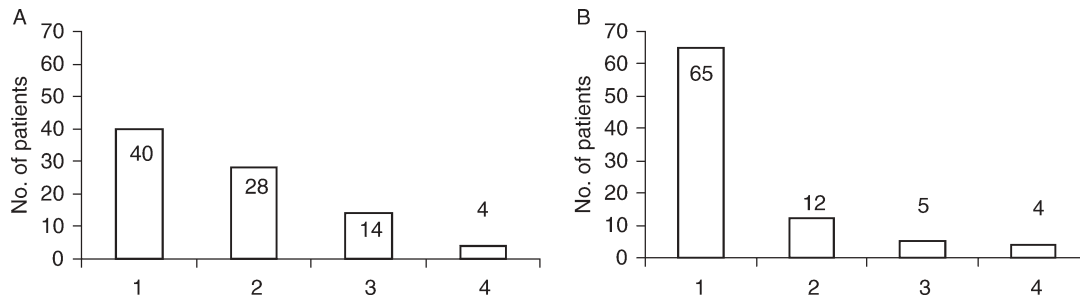


Fig 1 Assessment of (A) ventilation and (B) view of structures inside the trachea at the time of tracheal puncture, graded as: 1, very good; 2, good; 3, difficult; and 4, not possible with ILM during PDT.

decrease in MV to <2 litre min^{-1} , or 'no possible ventilation' both occurred in 18 (21%) of the patients (Fig. 1). In 14 of these patients, PDT could be continued after correction of the ILM position. Passing the bronchoscope through the glottis was feasible in 77% of patients without any problems. In some patients (20%), there was a gap of only 1–4 mm between the tongue and the pharynx, causing a more difficult passage. A swelling of the vocal chords was not a problem in any case. The rating of identification of the relevant structures inside the trachea as ring cartilage, first tracheal cartilages were 'very good' or 'good' in 90% of PDTs (Table 2; Fig. 1).

Discussion

This observational study describes our experience using the ILM for PDT in 86 patients. We introduced the ILM for ventilation during PDT after repeated damage to bronchoscopes. We have demonstrated that the proposed advantages of the ILM were, for the most part, confirmed in practice. Positioning of the bronchoscope tip just below the vocal chords is possible with the ILM. Nevertheless, accidental extubation does not occur and damaging of the bronchoscope is very unlikely. An additional assistant securing the airway is not necessary. We found an excellent view of the relevant structures, which in our experience was definitely better than that with an ETT.

We use the ILM instead of the LMA classic because of the facility of re-intubating the trachea in an emergency.^{14 15 18 19} Insertion of, and ventilation through the ILM, was possible in almost all the cases. In the four cases with insufficient ventilation or difficulty in inserting the ILM, we re-intubated the trachea without any problems.

Potential difficulties from ventilating through an ILM after prolonged tracheal intubation may result from glottic oedema in about 10% of cases.^{20 21} However, in our patients, difficulty in ventilation was due to incorrect positioning of the ILM, as shown by bronchoscopy.

Potential problems using the ILM have to be balanced against the potential risks using the ETT. In our study, minute volume was not as good as before the operation (Table 1). This may have some implications, especially in

neurosurgical patients. However, it is questionable that ventilation with ILM is worse than with ETT. During PDT, the cuff of the ETT has to be deflated and the tube partially withdrawn. In this situation, MV decreases markedly because of airway leakage and tube obstruction by the bronchoscope. Studies comparing the ETT and the LMA during PDT have found similar ventilation in both groups¹³ or more effective ventilation with the LMA, as evaluated by blood gas analysis.¹¹ One study rated the ventilation with the LMA worse when compared with the ETT. However, in that study, 33% of the patients in the LMA group had 'potentially catastrophic complications', and the ETT was judged as 'basically safe', despite accidental extubation in 3%, piercing of the ETT in 7%, and puncture of the cuff in 7% of cases.⁶ The overall complication rate during PDT with a LMA was 7.7%.¹¹ Although accidental extubation during PDT was frequent using an ETT,^{2 7} there is limited risk of losing the airway with an ILM. Therefore, the procedure can be performed with only two persons, and there is no need for an additional assistant to secure the airway.

In our institutions, a further motivation to use the ILM instead of the ETT was the high frequency of bronchoscope damage by the puncture needle. Although this complication is only sporadically mentioned in medical literature,² in practice damage to the bronchoscope happens frequently. By using the ILM instead of the ETT, this complication may be avoided reliably.

As a result of advantages shown in this study, our institutions now use an ILM instead of an ETT as the standard ventilatory device during PDT. These potential advantages include low risk of accidental tube puncture, extubation or bronchoscope damage, and no need for an additional assistant. This observational study sets the scene for a prospective, randomized trial of ILM and ETT for PDT.

References

- 1 Walz MK. Tracheostomie: Indikationen, Methoden, Risiken. *Chirurg* 2001; **72**: 1101–10
- 2 Treu TM, Knoch M, Focke N, Schulz M. Die perkutane dilatative Tracheostomie als neues Verfahren in der Intensivmedizin.

- Durchführung, Vorteile und Risiken. *Dtsch Med Wochenschr* 1997; **122**: 599–605
- 3 Heuer B, Deller A. Früh- und Spätkomplikationen der perkutanen Dilatationstracheostomie (PDT Ciaglia) bei 195 Intensivpatienten. *Anästhesiol Intensivmed Notfallmed Schmerzther* 1998; **33**: 306–12
 - 4 Kirkpatrick MB, Smith JR, Hoffman PJ, Middleton RMI. Bronchoscope damage and repair costs: result of a regional postal survey. *Respir Care* 1992; **37**: 1256–9
 - 5 Westphal K, Byhahn C, Lischke V. Tracheostomy in intensive care. *Anaesthesist* 1999; **48**: 142–56
 - 6 Ambesh SP, Sinha PK, Tripathi M, Matreja P. Laryngeal mask airway vs endotracheal tube to facilitate bedside percutaneous tracheostomy in critically ill patients: a prospective comparative study. *J Postgrad Med* 2002; **48**: 11–5
 - 7 Bause H, Prause A, Schulte am Esch J. Indikation und Technik der perkutanen Dilatationstracheostomie für den Intensivpatienten. *Anästhesiol Intensivmed Notfallmed Schmerzther* 1995; **30**: 492–6
 - 8 Beiderlinden M, Walz MK, Sander A, Groeben H, Peters J. Complications of bronchoscopically guided percutaneous dilatational tracheostomy: beyond the learning curve. *Intensive Care Med* 2002; **28**: 59–62
 - 9 Verghese C, Rangasami J, Kapila A, Parke T. Airway control during percutaneous dilatational tracheostomy: pilot study with the intubating laryngeal mask. *Br J Anaesth* 1998; **81**: 608–9
 - 10 Koitschev A, Graumueller S, Dommerich S, Kiotschev C, Simon C. Tracheostomy in intensive care medicine. Is the ENT specialist still needed? *HNO* 2003; **51**: 616–20
 - 11 Dosemeci L, Yilmaz M, Gürpınar F, Ramazanoglu A. The use of the laryngeal mask airway as an alternative to the endotracheal tube during percutaneous dilatational tracheostomy. *Intensive Care Med* 2002; **28**: 63–7
 - 12 Craven RM, Laver SR, Cook TM, Nolan JP. Use of the Pro-Seal LMA facilitates percutaneous dilatational tracheostomy. *Can J Anaesth* 2003; **50**: 718–20
 - 13 Grundling M, Kuhn SO, Riedel T, Feyerherd F, Wendt M. Application of the laryngeal mask for elective percutaneous dilatation tracheostomy. *Anaesthesiol Reanimat* 1998; **23**: 32–6
 - 14 Brain AL. Improving success with the intubating laryngeal mask airway. *Anaesthesia* 2001; **56**: 384–5
 - 15 Smart NG, Varveris DA, Jacobs P. Use of the intubating laryngeal mask in failed intubation associated with amyloid macroglossia. *Br J Anaesth* 2002; **89**: 186–7
 - 16 Griggs WM, Worthley LIG, Gilligan JE, Thomas PD, Myburg JA. A simple percutaneous tracheostomy technique. *Surg Gynecol Obstet* 1990; **170**: 543–5
 - 17 Plummer AL, Gracey DR. Consensus conference on artificial airways in patients receiving mechanical ventilation. *Chest* 1989; **96**: 178–80
 - 18 Maclachlan K, Skinner C, Verghese C. The intubating laryngeal mask airway in failed and difficult intubation. *Anaesthesia* 1999; **54**: 401–2
 - 19 Langenstein H, Möller F. Der Stellenwert der Larynxmaske bei schwieriger Intubation und erste Erfahrungen mit der Intubationslarynxmaske Fasttrach. *Anaesthesiol Intensivmed Notfallmed Schmerzther* 1998; **33**: 771–80
 - 20 de Bast Y, de Backer D, Moraine JJ, Lemaire M, Vandenberght C, Vencent JL. The cuff leak test to predict failure of tracheal extubation for laryngeal edema. *Intensive Care Med* 2002; **28**: 1267–72
 - 21 Jaber S, Chanques G, Matecki S, et al. Post-extubation stridor in intensive care unit patients. Risk factors evaluation and importance of the cuff-leak test. *Intensive Care Med* 2003; **29**: 69–74